

## Assessment of buccal bone thickness of aesthetic maxillary region in Nepalese adults: A Cone Beam Computed Tomography (CBCT) Study

Shrestha B<sup>1</sup>, Kurtzman GM<sup>2</sup>, Basnet BB<sup>3</sup>, Adhikari G<sup>4</sup>, Rokaya D<sup>5</sup>

<sup>1</sup>Lecturer, Department of Prosthodontics, Kantipur Dental College, Kathmandu, Nepal.

<sup>2</sup>Private Practitioner, 3801 International Drive, Suite 102 Silver Spring, MD 20906, USA.

<sup>3</sup>Assistant Professor, Department of Prosthodontics, College of Dental Surgery, B.P. Koirala Institute of Health Sciences, Dharan, Nepal.

<sup>4</sup>Lecturer, Department of Dentistry, Nepalese Army Institute of Health Sciences (NAIHS), Shree Birendra Hospital (SBH), Kathmandu, Nepal.

<sup>5</sup>Lecturer, Department of Clinical Dentistry, International College of Dentistry, Walailak University, Bangkok, Thailand.

### Abstract

**Introduction:** The dental implant has now become a routine treatment for oral rehabilitation.<sup>1</sup> The treatment planning and positioning of implants is greatly dependent upon the clinicians' understanding of the alveolar architecture of the maxilla and mandible.<sup>2-4</sup> In the esthetic zone, the implants therapy can be successful only if it is in harmony with the surrounding tissues.

**Objectives:** To study the labial osseous wall thickness of the anterior maxillary bone at various sites apical to the cemento-enamel junction using the cone beam computed tomography (CBCT).

**Materials and Methods:** Cone beam tomographic scans of 150 Nepalese adults (70 females and 80 males) were obtained from the Oral Radiology Unit, Kantipur Dental College Teaching Hospital & Research Center. CBCT scans were carried out by trained technicians using CS 9300 (Carestream Dental, Atlanta, GA, USA). In the CBCT images, distances between the CEJ and alveolar crest (AC) as well as the labial bone thickness at different levels (at the crest, 1mm, 3mm and 5 mm) were measured for central incisor (CI), lateral incisor (LI), and canine (C).

**Results:** It showed that the average distance between CEJ and crest of CI, LI, and C were 1.98±0.84 mm, 2.09±0.83 mm, and 2.12±1.20 mm, respectively. Only 3.3% of the CI, 10.7% of the LI, and 13.3% of the C showed a thick labial bone (1–2 mm) at the crestal level. At the 1 mm level, 75.3% of the CI, 64.5% of LI, and 70% C showed a very thin bony wall. Similarly, none showed very thick bony wall (>2mm). The thickness level was significant at the crest and at 5 mm level. The highest bone thickness of LI was found at the 1 mm level. In addition, there was also significant difference in different levels of LIs. The mean distance between the CEJ and the AC for the CI and the C was significantly higher in males than females.

**Conclusion:** The labial bone in the anterior maxilla is inherently thin, with more than 80% of the sites showing less than 1 mm. The results of this study may be useful for the implant planning in the esthetic zone and it is recommended tissue augmentation (soft and hard) to achieve esthetic emergence profile.

**Key words:** Cone beam computed tomography; Dental implants; Labial bone; Maxilla

*Conflict of Interest: No*

#### \*Corresponding Author

Dr. Bidhan Shrestha  
Lecturer, Department of Prosthodontics,  
Kantipur Dental College, Kathmandu, Nepal.  
E-mail: bidhanbpkihs@gmail.com

### Introduction

The dental implant has now become a routine treatment for oral rehabilitation.<sup>1</sup> The treatment planning and positioning of implants is greatly dependent upon the clinicians' understanding of the alveolar architecture of the maxilla and mandible.<sup>2-4</sup> In the esthetic

zone, the implants signify the harmony of the surrounding tissues with the definitive restoration. Using the triangle of bone decision tree, the projected implant site is depicted in a buccolingual slice from the CBCT scan. The apex of the triangle is oriented toward the height of the alveolar ridge and the projected site for the implant platform. The base is oriented toward the apical extent of the implant fixture and terminates at the most apical extent of the available bone. Understanding of the “triangle of bone” present in the anterior maxilla aids in implant placement enclosing the implant circumferentially within bone and avoiding potential surgical and restorative issues.<sup>5</sup>

The facial wall is a key factor for the esthetic outcome in implant dentistry. Hence, precise evaluation of the labial wall before surgery aids in proper treatment planning with high success rate. Although the immediate placement of implants is thought to preserve the shape of the alveolar bone, it doesn't prevent the natural remodeling procedure, particularly of the buccal osseous plate.<sup>6-8</sup> At least 1-2 mm of buccal bone in the anterior maxilla is needed for adequate soft tissue support and an optimal esthetic outcome.<sup>9</sup> Optimal esthetic outcomes are greatly dependent upon the ideal three-dimensional (3D) positioning of the implant to ensure that adequate buccal bone and tissue biotype is present. Diagnostic imaging thus plays a key role for correct implant placement.<sup>9-13</sup> At present, cone beam computed tomography (CBCT) is a standard 3D diagnostic radiographic system utilized in treatment planning of dental implants.<sup>14-16</sup> With a low radiation dosage, affordable price, high resolution and the accuracy of measurements through multiple planar formatted images have now made CBCT the method of choice for treatment planning of dental implants for many clinicians.<sup>17,18</sup> The buccal and lingual osseous plate thickness can now be measured with greater precision with the help of the

CBCT, allowing the clinician to plan accurately to prevent catastrophic events like fenestration and dehiscence around the implant site due to inadequate buccal osseous thickness.<sup>19</sup>

This study aimed to investigate the labial osseous wall of the anterior maxilla at various sites apical to the CEJ using the CBCT. In addition, the thickness of the buccal osseous plates was investigated in males and females.

## Materials and Methods

Study proposal was approved by the Institutional Review Board (IRB) of Kantipur Dental College Teaching Hospital & Research Center and ethical clearance was obtained. The CBCT scans were studied from the database of the Oral Radiology Unit, Kantipur Dental College Teaching Hospital & Research Center over a period of 9 months from June 2018 to February 2019. All the CBCT scans were carried out by a trained technologist from the CBCT unit (CS9300CBCT, Carestream Dental, Atlanta, GA, USA) with the following settings: 85 kV, 12 mA, 0.1mm voxel size and a 17 x 13cm field of view. Sample size was estimated to be 138 based on the prevalence rate in a previous study.<sup>20</sup> The CBCT images were obtained from Nepalese subjects for dental purposes, such as oral surgery, dental implant, and orthodontic purpose and were studied in CS 3D software (Carestream Dental, Atlanta, GA, USA).

The inclusion criteria were properly exposed CBCT with adequate contrast, presence of six maxillary anterior teeth [central incisor (CI), lateral incisor (LI), and canine(C)], no pathologies in anterior maxilla, and no evidence of periodontal bone loss. The exclusion criteria were the CBCT scans of subjects with mal-aligned and crowded teeth, undergoing orthodontic therapy, root resorption, periodontal involvement, any pathologies in maxillary anterior area, metal or zirconia crowns in the anterior maxillary region, and distorted images.

The labial osseous plates thickness were measured in the labial-palatal direction perpendicular to the long axis of the tooth root.<sup>21-23</sup> The measurements were recorded at 4 locations in sagittal section: at the crest (L0), 1 mm (L1), 3 mm (L3) and 5 mm (L5) apical to the crest for each tooth as shown in Fig 1. The CBCT cross-section of a CI, LI and C demonstrating a thin buccal osseous plate along the root length is shown in Fig 2. Additionally, the distance between the alveolar crest and CEJ were measured. A single investigator performed all the measurements using the computer software. Descriptive statistics were calculated. Measurements at different levels of each tooth were tested by Friedman's test using SPSS version 18 at the significance level at  $P < 0.05$ . For statistically significant data, Wilcoxon signed rank test was used to do the pair-wise comparisons. In addition, Mann-Whitney U-test was done to compare between the 2 genders. Finally, Spearman's correlation was done to determine the relationship between the age and thickness of bone at different levels of the CI, LI, and C.

## Results

The study was conducted in CBCT images of 450 teeth of 150 patients (70 females and 80 males) as shown in Table 1. The measurements at different levels (L0, L1, L3, L5) were distributed into three categories according to the teeth CI, LI and C (Table 2). At the crest level (L0), thick labial bone (1-2mm) was prevalent in 3.3% of CIs, 10.7% of LIs and 13.3% of Cs. Most LIs (46%) showed very thin osseous wall ( $< 0.5$  mm) whereas, thin (0.5–1mm) osseous wall was present in 66% of CIs, 43.3% of LIs and 54% of Cs.

At L1 level (1 mm apical to the crest), 70% C, 64.7% of LIs and 75.3% of CIs exhibited thin osseous walls. At the L5 level, very thin osseous wall was observed in most of the LIs and Cs

(Table 2). None of the teeth at any level showed a very thick osseous wall ( $> 2$ mm).

The descriptive statistics of the osseous thickness at different levels is shown in Table 3. The comparisons of osseous thickness of each tooth at different levels between males and females of CI, LI and C are shown in Table 4-6. Males demonstrated statistically significant higher mean osseous thickness at 1 mm ( $P = 0.007$ ) and 5 mm ( $P = 0.031$ ) of CIs and at 5 mm of LIs ( $P < 0.001$ ). But, at other levels of measurement, there was no significant difference between gender. The distance from the alveolar crest (AC) and CEJ was significantly higher ( $P < 0.001$ ) in males for CIs and Cs, whereas there was no significant difference in case of LIs ( $P = 0.104$ ).

The results of comparison of osseous thickness of teeth at different levels is shown in Table 7. The osseous thickness at various levels for the Cs showed a significant lower thickness levels at the crest, L0 and L5 levels. Highest osseous

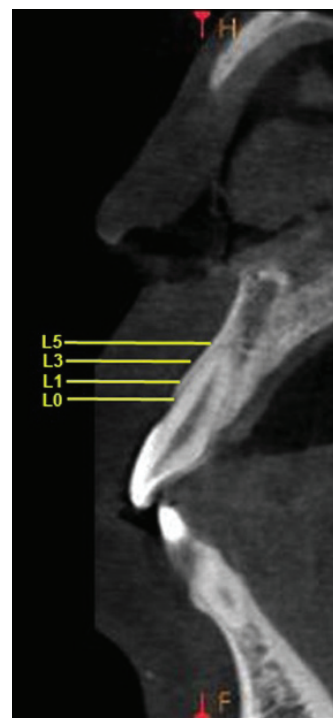


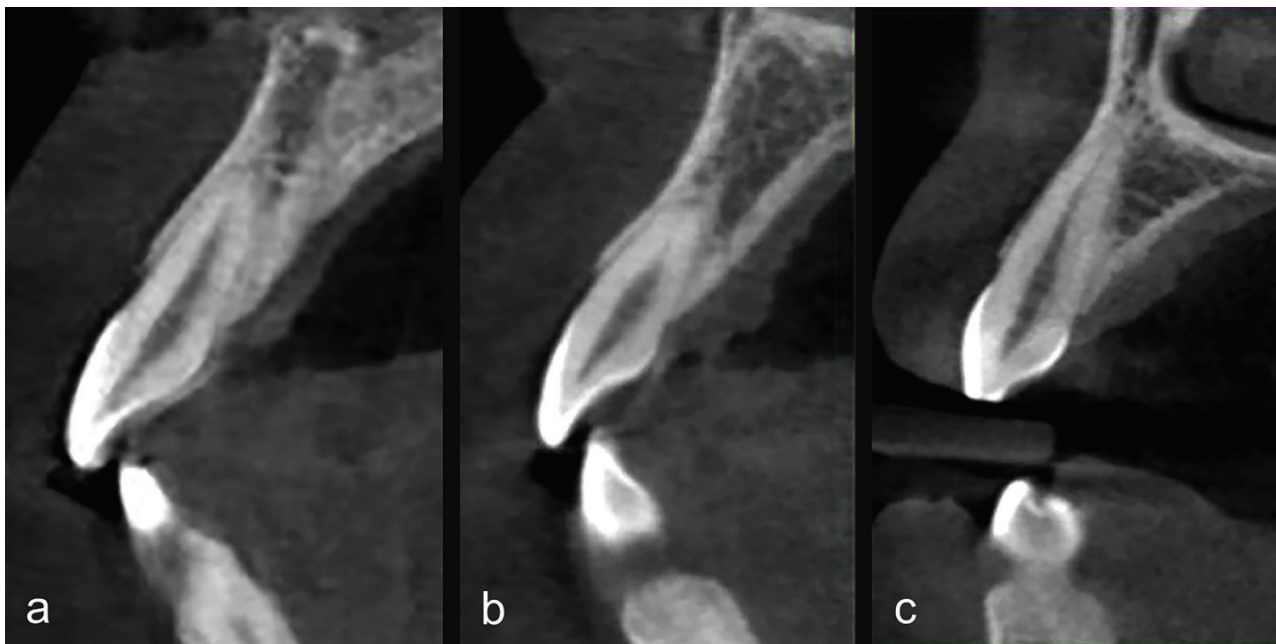
Figure 1: CBCT cross-section of a healthy maxillary central incisor demonstrating a thickness of buccal osseous plate along the roots length at different locations.

thickness of the LIs was found at the L1 level. A statistically significant difference was observed at different levels of the LIs except for L0 and L3 levels.

Table 8 shows the results of comparison of osseous thickness of teeth at different levels in the two genders. The CIs in females demonstrated statistically significantly higher osseous thickness at the 1 mm level. The LI and C showed significant lower osseous thickness at the 5 mm level. In males, the crestal level (L0) showed significant lower osseous thickness regarding the CI. For the LI and C, the lowest osseous thickness was exhibited at L5. As

the osseous thickness at different levels was compared, a significant difference was not observed between L1 and L3, L1 and L5 and L3 and L5 in males.

Finally, Spearman's correlation between age and osseous thickness at different levels of the central incisor, lateral incisor and canine is shown in Table 9. A weak negative correlation was seen between age and thickness of bone at 1 mm from the crest of the CI ( $r_s = -0.335$ ,  $n=150$ ,  $P<0.001$ ), but a positive mild correlation was observed for the LI at the 5 mm level ( $r_s = 0.203$ ,  $n=150$ ,  $P<0.013$ ). For C, a weak positive correlation was seen at the 3 mm and 5 mm level (Table 8).



*Figure 2a: CBCT cross section of a maxillary central incisor demonstrating a thin buccal osseous plate along the root length.*

*Figure 2b: CBCT cross section of a maxillary lateral incisor demonstrating a thin buccal osseous plate along the root length.*

*Figure 2c: CBCT cross section of a maxillary canine demonstrating a thin buccal osseous plate along the root length.*



**Table 1:** Study subject distribution by gender, age, and tooth type.

Variables	Frequency
Gender distribution	N=150
Male	70 (46.7)
Female	80 (53.3)
Mean age (years) $\pm$ SD	25.37 $\pm$ 6.364
Age groups	
<20 years	28 (18.7)
21-30	98 (65.3)
>31	24 (16.0)
Total number of teeth	450
Central incisor (CI)	150
Lateral incisor (LI)	150
Canine (C)	150

**Table 2:** Osseous thickness distribution at different levels (n=150).

Tooth	Level	<0.5 mm	0.5 – 1 mm	1 – 2 mm
Central incisor	Crestal (L0)	46 (30.7%)	99 (66%)	5 (3.3%)
	At 1 mm (L1)	21 (14%)	113 (75.3%)	16 (10.7%)
	At 3 mm (L3)	33 (22%)	101 (67.3%)	16 (10.7%)
	At 5 mm (L5)	41 (27.3%)	101 (67.3%)	8 (5.3%)
Lateral incisor	Crestal (L0)	69 (46%)	65 (43.3%)	16 (10.7%)
	At 1 mm (L1)	33 (22%)	97 (64.7%)	20 (13.3%)
	At 3 mm (L3)	65 (43.3%)	68 (45.3%)	17 (11.3%)
	At 5 mm (L5)	105 (70%)	41 (27.3%)	4 (2.7%)
Canine	Crestal (L0)	49 (32.7%)	81 (54%)	20 (13.3%)
	At 1 mm (L1)	21 (4%)	105 (70%)	24 (16%)
	At 3 mm (L3)	24 (16%)	90 (60%)	36 (24%)
	At 5 mm (L5)	78 (52%)	52 (34.7%)	20 (13.3%)

**Table 3:** Descriptive statistics of different parameters.

Level	Statistics	Central incisor	Lateral incisor	Canine
CEJ-alveolar crest	Mean $\pm$ SD	1.986 $\pm$ 0.843	2.095 $\pm$ 0.832	2.124 $\pm$ 1.207
	Median (Interquartile range)	2 (1.275 - 2.5)	1.9 (1.6 - 2.7)	2 (1.25 - 2.6)
Bone thickness at crest	Mean $\pm$ SD	0.644 $\pm$ 0.226	0.612 $\pm$ 0.243	0.705 $\pm$ 0.261
	Median (Interquartile range)	0.6 (0.5 - 0.8)	0.6 (0.4 - 0.7)	0.7 (0.5 - 0.8)
Bone thickness at 1 mm	Mean $\pm$ SD	0.773 $\pm$ 0.197	0.779 $\pm$ 0.259	0.836 $\pm$ 0.263
	Median (Interquartile range)	0.7 (0.6 - 0.9)	0.8 (0.6 - 0.9)	0.8 (0.6 - 1)
Bone thickness at 3 mm	Mean $\pm$ SD	0.7467 $\pm$ 0.231	0.664 $\pm$ 0.321	0.81 $\pm$ 0.311
	Median (Interquartile range)	0.7 (0.6 - 1)	0.6 (0.4 - 0.9)	0.7 (0.6 - 1)
Bone thickness at 5 mm	Mean $\pm$ SD	0.688 $\pm$ 0.222	0.504 $\pm$ 0.236	0.626 $\pm$ 0.292
	Median (Interquartile range)	0.7 (0.5 - 0.8)	0.5 (0.3 - 0.6)	0.5 (0.4 - 0.8)

**Table 4:** Comparison of thickness of bone between the two genders of central incisor.

Level	Statistics	Female (n=70)	Male (n=80)	P-value
CEJ-AC	Mean±SD	1.647±0.711	2.283±0.841	<0.001*
	Median (interquartile range)	1.70(1.075-2.0)	2.5(1.6-2.70)	
Bone thickness at crest	Mean±SD	0.638±0.266	0.65 ±0.184	0.696
	Median (interquartile range)	0.70(0.40 – 0.80)	0.60 (0.5 – 0.77)	
Bone thickness at 1 mm	Mean±SD	0.822±0.196	0.73±0.189	0.007*
	Median (interquartile range)	0.70 (0.70-1)	0.70 (0.6 –0.9)	
Bone thickness at 3 mm	Mean±SD	0.702±0.207	0.785±0.245	0.118
	Median (interquartile range)	0.70(0.5 - 0.8)	0.70 (0.6 - 1)	
Bone thickness at 5 mm	Mean±SD	0.645±0.243	0.725±0.195	0.031
	Median (interquartile range)	0.60(0.4 - 0.8)	0.7(0.60 -0.9)	

**Table 5:** Comparison of thickness of bone between the two genders of lateral incisor.

Level	Statistics	Female (n=70)	Male (n=80)	P-value
CEJ-AC	Mean±SD	1.936±0.721	2.233±0.899	0.104
	Median (interquartile range)	1.8(1.5 - 2.3)	1.95 (1.62 – 2.9)	
Bone thickness at crest	Mean±SD	0.644±0.281	0.585±0.223	0.945
	Median (interquartile range)	0.5(0.5 -0.7)	0.60 (0.40 – 0.70)	
Bone thickness at 1 mm	Mean±SD	0.778±0.314	0.78±0.20277	0.153
	Median (interquartile range)	0.7(0.5 - 0.8)	0.8(0.6 - 0.9)	
Bone thickness at 3 mm	Mean±SD	0.641±0.335	0.685±0.308	0.234
	Median (interquartile range)	0.6(0.4 -0.82)	0.70 (0.42-0.9)	
Bone thickness at 5 mm	Mean±SD	0.43±0.22	0.57±0.231	<0.001*
	Median (interquartile range)	0.4(0.3 - 0.5)	0.5(0.4 - 0.77)	

**Table 6:** Comparison of thickness of bone between the two genders of canine.

Level	Statistics	Female (n=70)	Male (n=80)	P-value
CEJ-AC	Mean ±SD	1.561 ±0.7432	2.617±1.319	<0.001*
	Median (interquartile range)	2.35 (2 - 2.7)	1.40(1.05-2.0)	
Bone thickness at crest	Mean ±SD	0.711 ±0.282	0.7±0.242	0.909
	Median (interquartile range)	0.7(0.47 - 0.9)	0.7 (0.5 – 0.8)	
Bone thickness at 1 mm	Mean ±SD	0.872±0.326	0.805±0.189	0.611
	Median (interquartile range)	0.8(0.6-1)	0.8(0.62 -0.975)	
Bone thickness at 3 mm	Mean ±SD	0.828±0.319	0.795±0.304	0.855
	Median (interquartile range)	0.7(0.6 - 0.9)	0.75(0.52-1.07)	
Bone thickness at 5 mm	Mean ±SD	0.611±0.28	0.64±0.304	0.568
	Median (interquartile range)	0.5(0.4-0.7)	0.7(0.32-0.8)	

**Table 7:** Results of comparison of osseous thickness of teeth at different levels (Friedman test).

Teeth type	P-value	Wilcoxon signed rank (pairwise comparison)
Central incisor	<0.001*	L0 – L1 (<0.001) L0 – L3 (<0.001) L0 – L5 (0.039) L1 – L3 (0.049) L1 – L5 (0.001) L3 – L5 (0.001)
Lateral incisor	<0.001*	L0 – L1 (<0.001) L0 – L3 (0.540) L0 – L5 (<0.001) L1 – L3 (<0.001) L1 – L5 (<0.001) L3 – L5 (<0.001)
Canine	<0.001*	L0 – L1 (<0.001) L0 – L3 (0.001) L0 – L5 (0.005) L1 – L3 (0.068) L1 – L5 (<0.001) L3 – L5 (<0.001)

\*significant different at P<0.05.

**Table 8:** Results of comparison of osseous thickness of teeth at different levels in the two genders (Friedman test).

Teeth type	Male		Female	
	P-value	Wilcoxon signed rank (pairwise comparison) <sup>‡</sup>	P-value	Wilcoxon signed rank (pairwise comparison) <sup>‡</sup>
Central incisor	<0.001	L0 – L1 (0.002) L0 – L3 (0.001) L0 – L5 (0.006) L1 – L3 (0.024) L1 – L5 (0.915) L3 – L5 (0.015)	<0.001*	L0 – L1 (<0.001) L0 – L3 (0.027) L0 – L5 (0.531) L1 – L3 (<0.001) L1 – L5 (<0.001) L3 – L5 (0.018)
Lateral incisor	<0.001	L0 – L1 (<0.001) L0 – L3 (0.303) L0 – L5 (0.347) L1 – L3 (0.015) L1 – L5 (<0.001) L3 – L5 (<0.001)	<0.001*	L0 – L1 (0.001) L0 – L3 (0.794) L0 – L5 (<0.001) L1 – L3 (<0.001) L1 – L5 (0.003) L3 – L5 (<0.001)
Canine	<0.001	L0 – L1 (<0.001) L0 – L3 (0.037) L0 – L5 (0.194) L1 – L3 (0.382) L1 – L5 (<0.001) L3 – L5 (<0.001)	<0.001*	L0 – L1 (<0.001) L0 – L3 (0.015) L0 – L5 (0.027) L1 – L3 (0.126) L1 – L5 (<0.001) L3 – L5 (<0.001)

\*significant different at P<0.05. <sup>‡</sup>For post-hoc analysis with Wilcoxon signed rank pairwise comparison Bonferroni adjustment was applied, thus the significance level was set at 0.0083.

**Table 9:** Spearman's correlation between age and osseous thickness at different levels of the central incisor, lateral incisor and canine.

Tooth	Thickness at crestr <sub>s</sub> (P-value)	At 1 mmr <sub>s</sub> (P-value)	At 3mmr <sub>s</sub> (P-value)	At 5 mmr <sub>s</sub> (P-value)
Central incisor	-0.085 (0.301)	-0.335 (<0.001*)	-0.112 (0.173)	0.029 (0.724)
Lateral incisor	-0.070 (0.391)	0.043 (0.603)	0.117 (0.153)	0.203 (0.013*)
Canine	0.057 (0.492)	0.019 (0.814)	0.168 (0.040*)	0.209 (0.010*)

\*significant difference at P<0.05.

## Discussion

The volume of facial osseous play an important role in the anterior esthetic by supporting the mucosa around dental implants. The height of the alveolar crest determine the occluso-gingival position of dental implant while the facial osseous thickness plays a greater role on the emergence profile of the prosthesis.<sup>24</sup> The CBCT images were used to study the thickness of the facial osseous wall in the maxillary esthetic zone in this study. In most of the cases, the facial osseous walls of maxillary anterior teeth are thin which is a risk factor for the implant placement owing to its substantial resorption following tooth extraction.<sup>7,8,25-27</sup> Osseous augmentation procedures and palatal placement of the implant fixtures have been recommended for optimal clinical outcomes of early and immediate implant placements in maxillary anterior region.<sup>28-31</sup>

In this present study, for the evaluation of the labial bone thickness, four readings (L0, L1, L3, and L5) were done that may potentially alter the placement of an immediate implant. The L0, L1, and L3 are more important than the reading at L5 as a measure of the crestal osseous architecture as they configure the alveolar process. The mean value at L1 and L3 levels showed a higher osseous thickness than at L0.

The labial bone thickness was greater in males than in females in L1, L3 and L5 regions. This difference in osseous thickness and density in males and females may be attributable to the

heavier masticatory forces and musculature exhibited by males compared to females as stated by other authors.<sup>32,33</sup> However, females showed greater alveolar osseous thickness at the level of the alveolar crest (L0) and less bone loss compared to male.<sup>34</sup>

In this study, the distances: bony crest to mid-labial point of CEJ were 1.99 mm (CI), 2.09 mm (LI), and 2.12 mm (C). These results were similar to the other studies done by Zekry et al., Wang et al., Januario et al, and El Nahass and Naiem.<sup>8,22,35,36</sup> In addition, there was difference in the CEJ to bone distances in CI and C region between male and female. The males demonstrated a greater distance in the LI region which is similar to the findings from other study.<sup>37</sup>

## Conclusion

The results of this study indicated that the labial bone in the anterior maxilla is thin, greater than 80% of the sites revealed bone thickness <1 mm. This result has a great implication on the treatment planning for implant placement in the esthetic zone, as either soft or hard tissue augmentation or a combination of both may be needed in most cases to achieve proper emergence profile and esthetics for long term success.

## Acknowledgement

The authors would like to sincerely thank Drs. Dilli Pun and Amrita Shrestha for their valuable assistance in the completion of this manuscript.



## Conflict of Interest

Authors declare that there is no conflict of interest.

## References

- Amornvit P, Rokaya D, Bajracharya S et al. Management of obstructive sleep apnea with implant retained mandibular advancement device. *World J Dent*. Epub ahead of print 2014.
- Adell R, Eriksson B, Lekholm U et al. Long-term follow-up study of osseointegrated implants in the treatment of totally edentulous jaws. *Int J Oral Maxillofac Implants* 1990;5: 347–359.
- Friberg B, Jemt T, Lekholm U. Early failures in 4,641 consecutively placed Brånemark dental implants: a study from stage 1 surgery to the connection of completed prostheses. *Int J Oral Maxillofac Implants* 1991;6:142–146.
- Schimmel M, Müller F, Suter V et al. Implants for elderly patients. *Periodontol 2000* 2017; 73: 228–240.
- Ganz SD. The triangle of bone--a formula for successful implant placement and restoration. *Implant Soc* 1995; 5: 2–6.
- Evans CDJ, Chen ST. Esthetic outcomes of immediate implant placements. *Clin Oral Implants Res* 2008; 19: 73–80.
- Araújo MG, Lindhe J. Dimensional ridge alterations following tooth extraction. An experimental study in the dog. *J Clin Periodontol* 2005; 32: 212–218.
- Januário AL, Duarte WR, Barriviera M et al. Dimension of the facial bone wall in the anterior maxilla: A cone-beam computed tomography study. *Clin Oral Implants Res* 2011; 22: 1168–1171.
- Grunder U, Gracis S, Capelli M. Influence of the 3-D bone-to-implant relationship on esthetics. *Int J Periodontics Restorative Dent* 2005; 25: 113–119.
- Buser D, Martin W, Belser UC. Optimizing esthetics for implant restorations in the anterior maxilla: anatomic and surgical considerations. *Int J Oral Maxillofac Implants* 2004; 19 Suppl: 43–61.
- Ferrus J, Cecchinato D, Pjetursson EB et al. Factors influencing ridge alterations following immediate implant placement into extraction sockets. *Clin Oral Implants Res* 2010; 21: 22–29.
- Chen ST, Darby IB, Reynolds EC. A prospective clinical study of non-submerged immediate implants: Clinical outcomes and esthetic results. *Clin Oral Implants Res* 2007; 18: 552–562.
- Braut V, Bornstein MM, Belser U, et al. Thickness of the anterior maxillary facial bone wall-a retrospective radiographic study using cone beam computed tomography. *Int J Periodontics Restorative Dent* 2011; 31: 125–131.
- Tyndall DA, Price JB, Tetradis S, et al. Position statement of the American Academy of Oral and Maxillofacial Radiology on selection criteria for the use of radiology in dental implantology with emphasis on cone beam computed tomography. *Oral Surg Oral Med Oral Pathol Oral Radiol* 2012; 113: 817–826.
- Benic GI, Elmasry M, Hämmerle CHF. Novel digital imaging techniques to assess the outcome in oral rehabilitation with dental implants: A narrative review. *Clin Oral Implants Res* 2015; 26: 86–96.
- Hämmerle CHF, Cordaro L, van Assche N et al. Digital technologies to support planning, treatment, and fabrication processes and outcome assessments in implant dentistry. Summary and consensus statements. The 4th EAO consensus conference 2015. *Clin Oral Implants Res* 2015; 26: 97–101.
- Carrafiello G, Dizonno M, Colli V, et al. Carrafiello G, Dizonno M, Colli V, et al: Comparative study of jaws with multislice computed tomography and cone-beam computed tomography. *Radiol Med* 2010;115:600-611. *Radiol Med* 2010; 115: 600–611.
- Sukovic P. Cone beam computed tomography in craniofacial imaging. *Orthod Craniofacial Res* 2003; 6: 31–36.
- de Menezes CC, Janson G, da Silveira Massaro C, et al. Reproducibility of bone plate thickness measurements with Cone-Beam Computed Tomography using different image acquisition protocols. *Dental Press J Orthod* 2010; 15: 143–149.

20. Zhixuan Zhou, Wu Chen, Ming Shen, Chao Sun, Jun Li NC. Cone beam computed tomographic analyses of alveolar bone anatomy at the maxillary anterior region in Chinese adults. *J Biomed Res* 2014; 28: 498–505.
21. Zekry A, Wang R, Chau ACM, et al. Facial alveolar bone wall width - a cone-beam computed tomography study in Asians. *Clin Oral Implants Res* 2014; 25: 194–206.
22. Wang H-M, Shen J-W, Yu M-F, et al. Analysis of Facial Bone Wall Dimensions and Sagittal Root Position in the Maxillary Esthetic Zone: A Retrospective Study Using Cone Beam Computed Tomography. *Int J Oral Maxillofac Implants* 2014; 29: 1123–1129.
23. Vera C, De Kok IJ, Reinhold D, Limpiphitanakorn P, Yap AK, Tyndall D CL. Evaluation of facial alveolar bone dimension of maxillary anterior and premolar teeth. *Int J Oral Maxillofac Implant* 2012; 27: 1514–1519.
24. Blanes RJ, Bernard JP, Blanes ZM, et al. A 10-year prospective study of ITI dental implants placed in the posterior region. II: Influence of the crown-to-implant ratio and different prosthetic treatment modalities on crestal bone loss. *Clin Oral Implants Res* 2007; 18: 707–714.
25. Huynh-Ba G, Pjetursson BE, Sanz M, et al. Analysis of the socket bone wall dimensions in the upper maxilla in relation to immediate implant placement. *Clin Oral Implants Res* 2010; 21: 37–42.
26. Capelli M, Testori T, Galli F, et al. Esthetic risk assessment of immediate implant: Position paper and proposal of a novel diagnostic parameter. *Ital Oral Surg* 2012; 11: 161–174.
27. Tomasi C, Sanz M, Cecchinato, et al. Bone dimensional variations at implants placed in fresh extraction sockets: A multilevel multivariate analysis. *Clin Oral Implants Res* 2010; 21: 30–36.
28. Miyamoto Y, Obama T. Dental cone beam computed tomography analyses of postoperative labial bone thickness in maxillary anterior implants: comparing immediate and delayed implant placement. *Int J Periodontics Restorative Dent* 2011; 31: 215–225.
29. Buser D, Wittneben J, Bornstein MM, et al. Stability of Contour Augmentation and Esthetic Outcomes of Implant-Supported Single Crowns in the Esthetic Zone: 3-Year Results of a Prospective Study With Early Implant Placement Postextraction. *J Periodontol* 2011; 82: 342–349.
30. Buser D, Halbritter S, Hart C, et al. Early Implant Placement With Simultaneous Guided Bone Regeneration Following Single-Tooth Extraction in the Esthetic Zone: 12-Month Results of a Prospective Study With 20 Consecutive Patients. *J Periodontol* 2009; 80: 152–162.
31. Buser D, Chen ST, Weber HP, et al. Early implant placement following single-tooth extraction in the esthetic zone: biologic rationale and surgical procedures. *Int J Periodontics Restorative Dent* 2008; 28: 441–451.
32. Usui T, Uematsu S, Morimoto T, et al. Change in maximum occlusal force in association with maxillofacial growth. *Orthod Craniofacial Res* 2007; 10: 226–234.
33. Braun S, Hnat WP, Freudenthaler JW, et al. A study of maximum bite force during growth and development. *Angle Orthod* 1996; 66: 261–264.
34. Shiau HJ, Reynolds MA. Sex Differences in Destructive Periodontal Disease: A Systematic Review. *J Periodontol* 2010; 81: 1379–1389.
35. Zekry A, Wang R, Chau ACM, et al. Facial alveolar bone wall width - a cone-beam computed tomography study in Asians. *Clin Oral Implants Res* 2014; 25: 194–206.
36. El Nahass H, N. Naiem S. Analysis of the dimensions of the labial bone wall in the anterior maxilla: A cone-beam computed tomography study. *Clin Oral Implants Res* 2015; 26: e57–e61. doi:10.1111/clr.12332.
37. Alsaffar Z, Shafshak S, Shokry S. Assessment of Labial and Palatal Alveolar Bone Thickness and Height in Maxillary Anterior Teeth in Saudi population Using Cone Beam Computed Tomography (CBCT). *Int J Contemp Dent* 2016; 7: 1–6.